

# Factors affecting the rate of dissolution of temporary sutureless amniotic membrane applied to the ocular surface

Michael Nolan, Maylon Hsu, M.D., Amy Lin, M.D.

Department of Ophthalmology, Loyola University Chicago, Stritch School of Medicine, Maywood, IL

## Introduction

Amniotic membrane transplantation to the ocular surface has been performed for a variety of conditions, including ocular burns, persistent epithelial defects, acute Stevens-Johnson syndrome, limbal stem cell deficiency, keratitis, and surgical defects after conjunctival excision<sup>1-6</sup>. Amniotic membrane is a biologic tissue which is secured to the ocular surface to not only fill gaps in corneal and conjunctival epithelium, but also promote epithelial healing and has anti-inflammatory, anti-fibrotic, anti-angiogenic, and antimicrobial properties<sup>1</sup>. There has been the introduction of a device which allows for temporary sutureless application of cryopreserved amniotic membrane without adhesive (ProKera, Bio-Tissue, Inc., Miami, FL). The device consists of a piece of amniotic membrane clipped to a polycarbonate ring, which is easily inserted and removed from the eye. When the device is placed on the ocular surface, the ring rests on the bulbar conjunctiva, encircling the cornea. The device is well-tolerated with minimal side effects<sup>4</sup>. Amniotic membrane has been noted to dissolve naturally over time. To date, there have not been any studies investigating factors which affect the rate of amniotic membrane dissolution. It is hypothesized that higher degrees of ocular inflammation may lead to much faster dissolution of the amniotic membrane. This study investigates the factors which affect the rate of amniotic membrane dissolution in ProKera devices used in the Department of Ophthalmology, Loyola University Medical Center in Illinois.

## Methods

This is a retrospective chart review of all patients who had insertion of a 15 or 16 mm ProKera device since June 2005. Non-healing corneal epithelial defect was the primary indication for ProKera. The etiology of corneal epithelial defects and exam findings at the time of placement were recorded. The etiologies were organized into the following categories: acute toxic epidermal necrolysis syndrome (TENS), chronic TENS, exposure keratopathy, neurotrophic ulcer, and infectious ulcer. Medications used during treatment with ProKera and the clinical outcomes were recorded. The median amniotic membrane dissolution rates for these groups were compared by Kruskal-

Wallis and Dunn's tests.

**Table 1. Clinical Characteristics of Patients Receiving Prokera**

ID	Age	Sex	Eye	Reason for Prokera	Disease Category	Dissolution time (days)	Outcome
1.1	11	Female	OD	TENS, epithelial defect	acute TENS / epithelial defect	4	Dissolved
1.2	11	Female	OS	TENS, epithelial defect	acute TENS / epithelial defect	4	Dissolved
2.1	69	Male	OD	neurotrophic ulcer	neurotrophic ulcer	27	Removed
3.1	7	Male	OD	TENS	chronic TENS	10	removed partially dissolved
3.2	7	Male	OS	TENS	chronic TENS	10	removed partially dissolved
3.3	7	Male	OD	TENS	acute TENS / epithelial defect	7	Dissolved
3.4	7	Male	OS	TENS	chronic TENS		Removed – replaced
3.5	7	Male	OS	TENS	chronic TENS	15	Dissolved
3.6	7	Male	OS	TENS	acute TENS / epithelial defect	8	Dissolved
3.7	7	Male	OD	corneal ulcer – MRSA	infectious ulcer	8	Dissolved
4.1	8	Male	OD	TENS, symblepharon, epithelial defect	acute TENS / epithelial defect	7	Dissolved
5.1	52	Male	OS	Alkaline burn - epithelial defect	epithelial defect		fell out day 4
6.1	79	Male	OD	TENS	acute TENS / epithelial defect	14	Dissolved
6.2	79	Male	OS	TENS	Acute TENS / epithelial defect	17	Dissolved
6.3	79	Male	OD	TENS	acute TENS / epithelial defect		deceased day 4
6.4	79	Male	OS	TENS	acute TENS / epithelial defect		deceased day 1
7.1	78	Female	OD	Epi defect 2/2 medial canthus fistula	exposure epithelial defect	6	Dissolved
7.2	78	Female	OD	Epi defect 2/2 medial canthus fistula	exposure epithelial defect	3	Dissolved
7.3	78	Female	OD	Epi defect 2/2 medial canthus fistula	exposure epithelial defect	4	Dissolved
7.4	78	Female	OD	Epi defect 2/2 medial canthus fistula	exposure epithelial defect		removed – 4
8.1	60	Female	OD	periobital rad, persistent epithelial defect	neurotrophic ulcer	12	Dissolved
9.1	23	Male	OD	Exposure Keratopathy 2/2 thermal burn eyelid	exposure epithelial defect	5	Dissolved
9.2	23	Male	OS	Exposure Keratopathy 2/2 thermal burn eyelid	exposure epithelial defect	2	Dissolved
9.3	23	Male	OS	Exposure Keratopathy 2/2 thermal burn eyelid	exposure epithelial defect	5	Dissolved
10.1	55	Male	OS	TENS, Symblepharon	acute TENS / epithelial defect		removed 3 – for AMT
11.1	21	Female	OS	K ulcer, h/o SJS	infectious ulcer		removed 4 – healed
12.1	70	Male	OD	persistent epithelial defect s/p vitrectomy	epithelial defect		fell out same day
12.2	70	Male	OD	persistent epithelial defect s/p vitrectomy	epithelial defect		removed 7 – healed

AMT = amniotic membrane transplant

## Results

This study involved 28 ProKera membranes used in 12 patients. 19 membranes remained in place until dissolution, and 9 devices were removed while the membranes were still intact. Between different disease categories, devices placed in eyes with epithelial defects secondary to corneal exposure dissolved the quickest (4.5 days), while devices in eyes with neurotrophic ulcers (19.5 days) and chronic TENS (10 days) lasted the longest. The median number of days until dissolution was significantly longer with versus without concurrent topical steroid treatments (10 vs. 5 days respectively, p = 0.0102).

## Results

**Table 2. Prokera Dissolution by Disease Category**

Disease Category	Total Prokera (n)	Prokera w/ Dissolution (n)	Median days until dissolution
Acute TENS/ epithelial defect	10	7	8.7
Chronic TENS	4	3	11.7
Epithelial defect	3	0	n/a
Exposure epithelial defect	7	6	4.1
Neurotrophic ulcer	2	2	19.5
Infectious Ulcer	2	1	8

**Table 3. Duration of Amniotic Membrane**

Duration of Prokera	N	Lagophthalmos	Conjunctival Injection	Corneal Neovascularization	Topical Steroid	Systemic Steroid
1-6 days	8	5	5	3	0	0
7-13 days	7	0	5	3	5	2
> 14 days	4	0	4	1	3	2

**Table 4. Topical Steroid Use and Duration of Amniotic Membrane**

Topical Steroid	Number	Median Duration (days)	P Value*
No	11	5	
Yes	8	10.5	0.0102

\* Significance measured by Dunn's Test

**Figure 1. Photographs of Prokera Device**

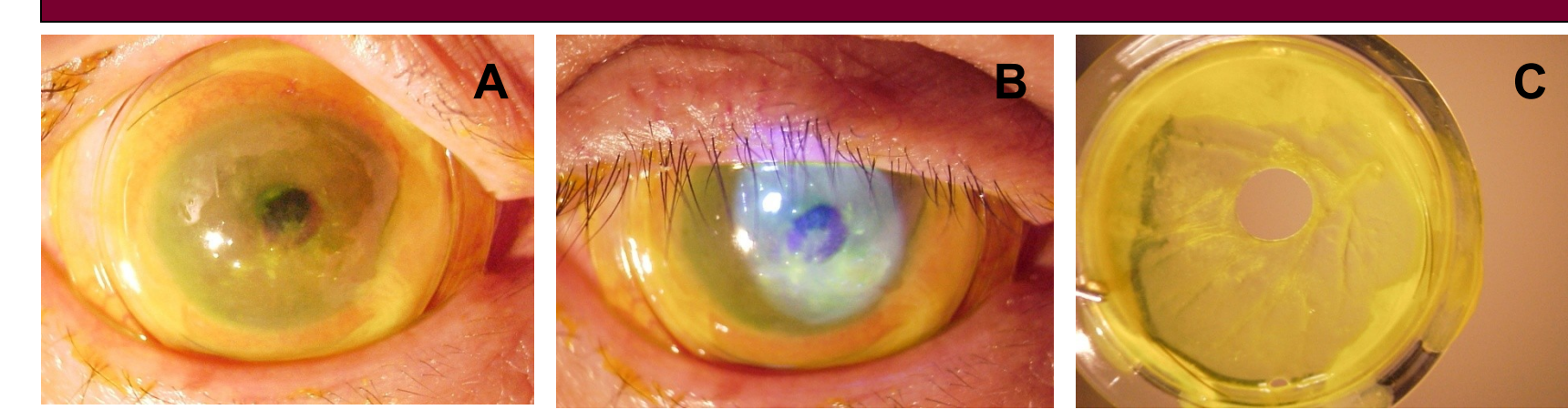


Figure 1. Photographs of Prokera device in an eye with a neurotrophic ulcer taken before breakdown began (A), under cobalt blue light (B), and after removal and central breakdown of the amniotic membrane (C).

## Conclusion

This study provides the first analysis of factors that influence the rate of dissolution of ProKera amniotic membranes. Patients were divided into 6 different disease categories. Patients with acute TENS/ corneal epithelial defect were the largest group in our study. Amniotic membranes dissolved the most quickly in eyes where exposure was the primary reason for epithelial defects. This finding suggests that desiccation may lead to more rapid break down of the membranes. Amniotic membranes in eyes receiving topical steroids had a significantly longer duration than those that did not. Topical steroids may also aid in limiting inflammatory processes that lead to amniotic membrane dissolution.

## References

1. Dua HS et al. The amniotic membrane in ophthalmology. *Surv Ophthalmol* 2004;49:51-77.
2. Gregory D. The ophthalmologic management of acute Stevens-Johnson syndrome. *The Ocular Surface* 2008;6:87-95.
3. Kheirkhah A et al. Temporary sutureless amniotic membrane patch for acute alkaline burns. *Arch Ophthalmol* 2008;126:1059-1066.
4. Pachigolla G et al. Evaluation of the role of ProKera in the management of ocular surface and orbital disorders. *Eye & Contact Lens* 2009;4:172-175.
5. Shammas MC et al. Management of acute Stevens-Johnson syndrome and toxic epidermal necrolysis utilizing amniotic membrane and topical corticosteroids. *Am J Ophthalmol* 2010;149:203-213.
6. Sheha H et al. Sutureless amniotic membrane transplantation for severe bacterial keratitis. *Cornea* 2009;28:1118-1123.